Clin. Lab. 2027;73:XXX-XXX
©Copyright

CASE REPORT

A Rare Case of *Mycobacterium abscessus* Infection in the Lumbar Region

Qimi Yuan, Ying Chen, Congshuang Xu

Department of Clinical Laboratory, Chengkou County Hospital of Traditional Chinese Medicine, Chongqing, China

SUMMARY

Background: **In December 2025, our hospital confirmed a rare case of *Mycobacterium abscessus* infection in the lumbar spine. The patient visited our hospital and presented with "back pain and left lower limb pain for 3 months". Three months ago, the patient experienced back pain without any apparent cause, which was persistent and throbbing. The patient also had radiating pain, numbness, and intermittent low-grade fever in the left lower limb. The patient then sought treatment at a local hospital. Lumbar magnetic resonance imaging (MRI) revealed lumbar disc herniation with radiculopathy. Subsequently, the patient underwent acupuncture and moxibustion therapy, which has been ongoing to date. However, the patient's back pain and left lower limb pain have not significantly improved. The patient came to our hospital for further examination and treatment. The outpatient department admitted the patient with the diagnoses of "1. Lumbar disc herniation with radiculopathy, 2. Infection". The patient's mental state is good, and there has been no significant change in body weight.**

Methods: **Clinical examinations include chest radiography, electrocardiogram, lumbar spine routine and dynamic radiography, echocardiography, CT-guided bone biopsy, posterior approach L5/S1 infection lesion clearance assisted by electromagnetic navigation microscope, spinal canal decompression, interbody and intertransverse process and facet joint fusion with bone grafting, and L4-S1 pedicle screw internal fixation. Other relevant examinations include blood routine, urine routine, liver function, renal function, histopathological biopsy, bacterial culture, acid-fast staining, NGS (Next-Generation Sequencing), blood glucose, electrolytes, etc.**

Results: **Lumbar magnetic resonance imaging (MRI): 1. Degenerative changes in the lumbar spine; instability of the L4-5 vertebral bodies. 2. Relative endplate inflammation of the L3-5 vertebral bodies. 3. Degeneration and protrusion of the L4/5 and L5/S1 intervertebral discs. 4. Abnormal signal intensity in the L5-S1 vertebral bodies, suggesting bone marrow edema. 5. Subcutaneous fasciitis and interspinous ligament inflammation in the lumbosacral region. 6. Sacral canal cyst. Pathological examination results of tissue samples: stromal fibrous tissue proliferation with degeneration, with numerous chronic inflammatory cells and scattered acute inflammatory cell infiltration. Auxiliary examination results: blood routine test: white blood cell count 18.93 × 10^9/L, neutrophil percentage 56.2%, total blood high-sensitivity C-reactive protein 16.29 mg/L; liver function test: total protein 60.7 g/L, albumin 34.9 g/L; lactate dehydrogenase 257.2 U/L, renal function test: urea 6.14 mmol/L, creatinine 35.90 µmol/L; coagulation function: D-dimer assay 720.78 FEU µg/L; glycated hemoglobin 7.60%; fasting glucose: fasting blood glucose 5.01 mmol/L, electrolytes: anion gap 7.10 mmol/L, potassium 2.88 mmol/L, calcium 1.96 mmol/L, erythrocyte sedimentation rate 63.0 mm/hour, inflammatory markers: interleukin-6 22.21 pg/mL, procalcitonin 0.053 ng/mL, erythrocyte sedimentation rate 50.0 mm/hour, T-SPOT binding infection test positive. Tissue sample acid-fast staining: positive. Tissue sample culture and identification (MALDI-TOF MS): *Mycobacterium abscessus*, tissue specimen NGS results showed *Mycobacterium abscessus*. Clinical treatment plan: amikacin injection (15 mg/kg qd ivgtt) plus imipenem/cilastatin (1 g q8h ivgtt) plus azithromycin capsules (250 mg qd po) for anti-infection treatment. After 10 days of treatment, the patient is in good condition. The patient and his family request to be discharged and continue anti-infection treatment at a local hospital.**

Conclusions: **This article reports a rare case of *Mycobacterium abscessus* infection in the lumbar region. The *Mycobacterium abscessus* strain was rapidly and accurately identified through MALDI-TOF MS and NGS testing. With appropriate clinical treatment measures, the patient improved and was discharged. It is hoped that this**

study will provide assistance for the clinical diagnosis and treatment of *Mycobacterium abscessus* infections in the future.
(Clin. Lab. 2027;73:xx-xx. DOI: 10.7754/Clin.Lab.2026.260112)

Case Report accepted January 12, 2026

Correspondence:
Congshuang Xu
Department of Clinical Laboratory
Chengkou County Hospital of Traditional Chinese Medicine
Chongqing
China
Email: 452830273@qq.com

KEYWORDS

Mycobacterium abscessus, NGS, MALDI-TOF MS

INTRODUCTION

Mycobacterium abscessus is a conditional pathogen which exists in the environment and belongs to a subgroup of non-tuberculous mycobacteria [1]. It can cause disseminated lesions in the lungs, lymph nodes, skin and soft tissues, bones and joints, as well as the whole body [2]. Due to the characteristics of such infections, such as difficult diagnosis, severe illness, long treatment cycles, and high medical costs, if the infection is not detected and properly treated in a timely manner, patients often suffer from recurrent infections and are difficult to cure. Previous case reports have mostly focused on lung diseases caused by *Mycobacterium abscessus*, while joint infections caused by it are relatively rare. Recently, our hospital admitted a patient with lumbar abscessus infection. Through correct and effective treatment, the patient's condition is currently stable. The report is as follows.

CASE PRESENTATION

Case

The patient, a 66-year-old female, presented to our hospital due to "low back pain and left lower limb pain for 3 months". Three months ago, the patient experienced low back pain without any apparent cause, which was persistent and throbbing. She also reported radiating pain, numbness, and intermittent low-grade fever in her left lower limb. She was subsequently admitted to a local hospital for treatment. Lumbar magnetic resonance imaging (MRI) revealed lumbar disc herniation accompanied by radiculopathy. She then underwent acupuncture and moxibustion therapy, which has been ongoing since then. However, there was no significant relief in her low back pain and left lower limb pain. She came to our hospital for further examination and treatment. The outpatient department admitted her for "1. Lumbar disc herniation accompanied by radiculopathy, 2. Infection". The patient's mental state was good, and there was no significant change in her weight. Clinical examinations included chest radiography, electrocardiogram, routine lumbar spine and dynamic radiography, echocardiogram, CT-guided bone biopsy, electromagnetic navigation microscope-assisted posterior lumbar 5/sacral 1 infection lesion clearance, spinal canal decompression, interbody and transverse process and facet joint fusion with internal fixation using lumbar 4-sacral 1 pedicle screws, and other related examinations: blood routine, urine routine, liver function, renal function, histopathological biopsy, bacterial culture, acid-fast staining, NGS detection, T-SPOT infection, blood glucose, electrolytes, etc. Lumbar MRI: 1. Lumbar degenerative changes; lumbar 4 - 5 vertebral instability. 2. Lumbar 3 - 5 vertebral relative endplate inflammation. 3. Lumbar 4/5 and lumbar 5/sacral 1 disc degeneration and herniation. 4. Abnormal signal shadow in lumbar 5-sacral 1 vertebrae, suggesting bone marrow edema. 5. Subcutaneous fasciitis and interspinous ligament inflammation in the lumbosacral region. 6. Sacral canal cyst. Pathological examination of tissue samples revealed interstitial fibrous tissue proliferation with degeneration, with a significant infiltration of chronic inflammatory cells and scattered acute inflammatory cells (Figure 1A). Auxiliary examination results: blood routine: white blood cell count 18.93 × 10^9/L, neutrophil percentage 56.2%, whole blood high-sensitivity C-reactive protein 16.29 mg/L; liver function test: total protein 60.7 g/L, albumin 34.9 g/L; lactate dehydrogenase 257.2 U/L; renal function test: urea 6.14 mmol/L, creatinine 35.90 μmol/L; coagulation function: D-dimer assay: 720.78 FEU ug/L; glycosylated hemoglobin: 7.60%; fasting glucose: fasting blood glucose: 5.01 mmol/L; electrolytes: anion gap 7.10 mmol/L, potassium 2.88 mmol/L, calcium 1.96 mmol/L; erythrocyte sedimentation rate (ESR) 63.0 mm/hour; inflammatory markers: interleukin-6 (IL-6) 22.21 pg/mL, procalcitonin 0.053 ng/mL; erythrocyte sedimentation rate (ESR) 50.0 mm/hour; T-SPOT binding infection: positive. Tissue sample acid-fast staining: positive (Figure 1C). Tissue sample culture and identification (MALDI-TOF MS): *Mycobacterium abscessus* (Figure 1B, D), tissue specimen NGS results showed: *Mycobacterium abscessus*. Clinical treatment plan: amikacin injection (15 mg/kg qd ivgtt) plus imipenem/cilastatin (1 g q8h ivgtt) plus azithromycin capsules (250 mg qd po) for anti-infection treatment. After 10 days of treatment, the patient's condition was good, and the patient and family requested to be discharged to a local

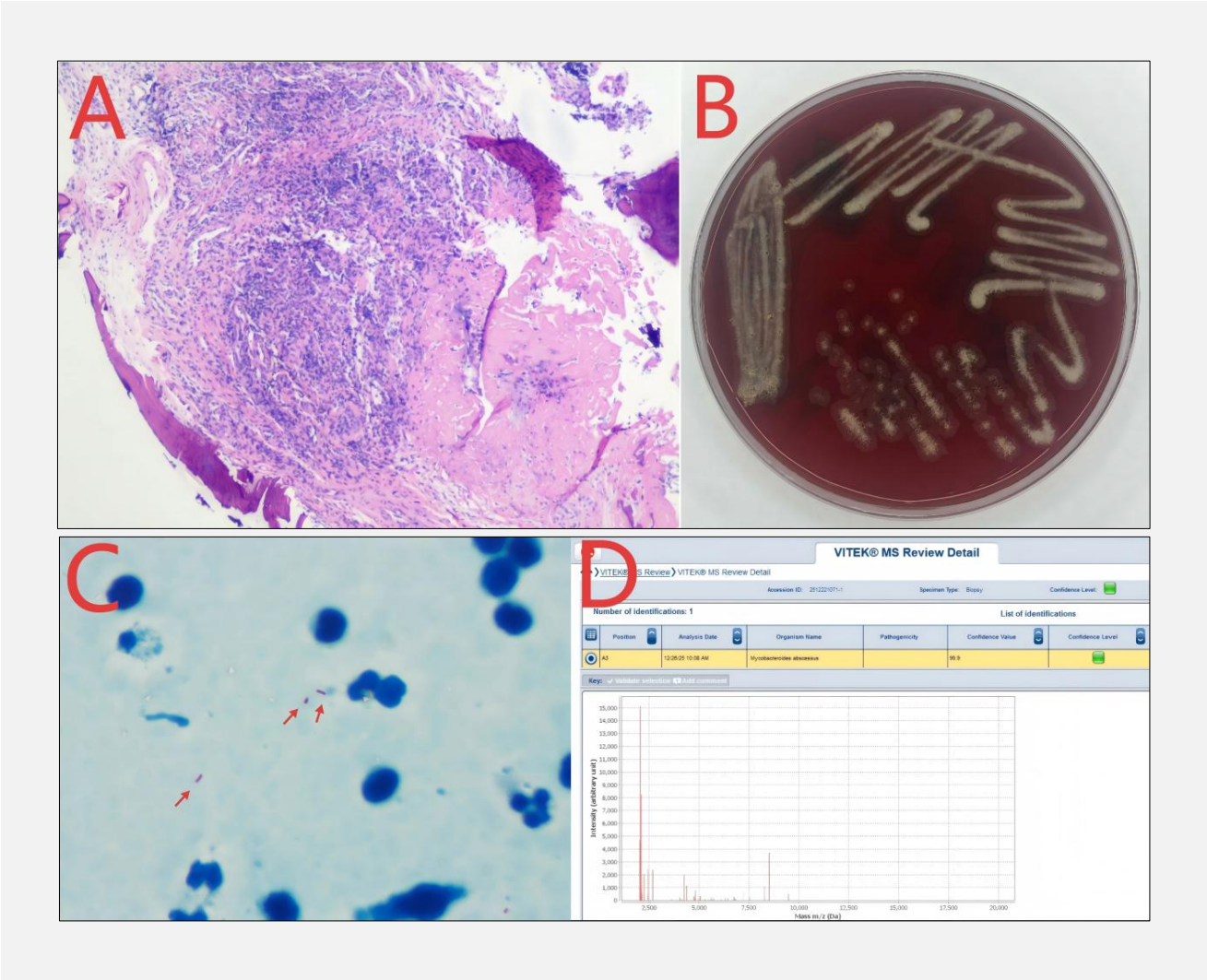

Figure 1. Clinical and bacteriological images.

A Histopathological examination: interstitial fibrous tissue proliferation with degeneration, accompanied by a significant infiltration of chronic inflammatory cells and scattered acute inflammatory cells.
B Growth of *Mycobacterium abscessus* in Blood agar medium at 35°C, 5% CO_2, 120 hours, aerobic cultivation.
C Acid fast staining of bacteria × 1,000.
D Identification results of *Mycobacterium abscessus* MALDI-TOF MS.

hospital for continued anti-infection treatment. Discharge instructions: 1. After discharge, it is recommended to administer amikacin for injection 0.6 g ivgtt qd plus azithromycin tablets 500 mg po qd plus linaclotide tablets 600 mg po qd for anti-infection treatment, with a course of 6 - 12 months. During medication, monitor the patient's renal function and platelet levels. 2. Enhance nutrition with a high-protein diet; 3. Mobilize the limbs to avoid thrombosis after bed rest; 4. After discharge, focus on bed rest in the near future and continue to strengthen lumbar and back muscle function exercises after 3 months; 4. Regular follow-up after surgery, with lumbar X-rays at 3 months, 6 months, and 1 year post-operation.

DISCUSSION

Mycobacterium abscessus is a type of conditional pathogen existing in the environment and a subgroup of non-tuberculous mycobacteria, capable of causing lesions in multiple sites such as the lungs, lymph nodes, and skin and soft tissues [3]. In recent years, non-tuberculous mycobacterial diseases have shown a rapid increase, becoming one of the significant public health issues threatening human health [4]. Previous case reports on *Mycobacterium abscessus* primarily focused on lung and skin and soft tissue diseases [5], with lumbar infections being rare. Recently, our hospital confirmed a case of *Mycobacterium abscessus* infection in the lumbar re-

gion. The patient had previously sought treatment at other hospitals with unsatisfactory results. Fortunately, they ultimately received a definitive diagnosis at our hospital, where appropriate clinical treatment measures were implemented, leading to improvement in their condition.

Mycobacterium abscessus can infect multiple parts of the body, with atypical clinical symptoms that are prone to misdiagnosis. Conventional diagnostic methods have a long cycle, which can easily delay patient treatment and increase economic burden [6]. Therefore, early detection and diagnosis are crucial for the treatment of such patients in clinical practice. Unfortunately, the patient in this case was initially treated for lumbar disc herniation with radiculopathy in other hospitals, with poor results. Eventually, she came to our hospital for treatment, and although satisfactory therapeutic effects were achieved, the etiology was not promptly identified in the early stage, leading to a prolonged disease cycle. During clinical treatment, the patient's relevant test indicators, such as inflammatory markers, interleukin-6, white blood cells, and whole blood high-sensitivity C-reactive protein, all showed varying degrees of elevation, suggesting the possibility of infection. Clinically, vancomycin combined with ceftriaxone was used for empirical anti-infective treatment on the one hand, and on the other hand, lumbar tissue samples were collected for bacterial culture, biopsy, mass spectrometry, and NGS testing. The final diagnosis was *Mycobacterium abscessus* infection of the lumbar region.

Previous studies have shown [7] that *Mycobacterium abscessus* exhibits high resistance to common antimicrobial drugs; in addition, the cell wall of this type of bacteria is highly hydrophobic, enabling it to form biofilms around joints, shielding it from the body's immune system and drugs and leading to an unclear correlation between in vitro drug sensitivity test results and clinical efficacy [8]. Therefore, these pathogenic characteristics make anti-infective treatment extremely challenging. Currently, according to the guidelines for the diagnosis and treatment of NTM disease issued by the American Thoracic Society, the British Thoracic Society, and the Chinese Medical Association Tuberculosis Branch, *Mycobacterium abscessus* requires the combination treatment of at least two or more sensitive antimicrobial drugs [9]. The conventional drug sensitivity tests for *Mycobacterium abscessus* mainly include clarithromycin, azithromycin, cefoxitin, and amikacin [10]. In this case, the clinical treatment involved amikacin injection (15 mg/kg qd ivgtt) plus imipenem/cilastatin (1g q8h ivgtt) plus azithromycin capsules (250 mg qd po), with close monitoring of treatment efficacy and liver and kidney function during medication. Fortunately, this case achieved satisfactory treatment results, and the patient improved and was discharged.

With the development of technology, microbial identification technology has gradually shifted from manual detection to instrument automation. Traditional detection methods suffer from issues such as low throughput, low automation, and slow detection speed [11]. Matrix-assisted laser desorption ionization-time of flight mass spectrometry (MALDI-TOF MS) can achieve accurate identification in as little as a few minutes [12]. This system, with its advantages of high efficiency, accuracy, and high throughput [13], has redefined modern microbial identification. Next-generation sequencing (NGS) gene detection is a high-throughput and high-precision gene analysis method [14] that can rapidly analyze genetic information in individual DNA or RNA. It is widely used in disease diagnosis, cancer treatment, genetic disease screening, personalized medicine, and other fields [15]. In this case study, both methods yielded consistent results in a short period of time, allowing for timely clinical adjustments to the medication regimen and effective and accurate treatment for the patient. Therefore, this case also demonstrates the significant advantages of these two methods over traditional methods in pathogen diagnosis.

In summary, this article reports a rare case of *Mycobacterium abscessus* infection in the lumbar spine. The *Mycobacterium abscessus* strain was rapidly and accurately identified through mass spectrometry and NGS testing. With reasonable clinical treatment measures, the patient improved and was discharged. It is hoped that this study will provide assistance for the clinical diagnosis and treatment of *Mycobacterium abscessus* infections in the future.

Consent for Publication:
The patient provided written informed consent for study publication.

Availability of Data and Materials:
The original data and materials presented in the study are included in the article/supplementary material. Further inquiries can be directed to the corresponding author.

Source of Funds:
This study was supported by the Chongqing Science and Health Joint Medical Research Project Fund (2022 QNXM034).

Declaration of Generative AI in Scientific Writing:
This manuscript and figures were not drafted and edited using artificial intelligence assisted writing tools.

Declaration of Interest:
The authors declare no competing interests.

References:

1. Cristancho-Rojas C, Varley CD, Lara SC, Kherabi Y, Henkle E, Winthrop KL. Epidemiology of *Mycobacterium abscessus*. Clin Microbiol Infect 2024 Jun;30(6):712-7. (PMID: 37778416)

2. Griffith DE, Daley CL. Treatment of *Mycobacterium abscessus* Pulmonary Disease. Chest 2022 Jan;161(1):64-75. (PMID: 34314673)

3. Griffith DE. *Mycobacterium abscessus* group pulmonary disease. Curr Opin Infect Dis 2025 Apr 1;38(2):169-75. (PMID: 39927482)

4. Victoria L, Gupta A, Gómez JL, Robledo J. *Mycobacterium abscessus complex*: A Review of Recent Developments in an Emerging Pathogen. Front Cell Infect Microbiol 2021 Apr 26;11: 659997. (PMID: 33981630)

5. Sur S, Patra T, Karmakar M, Banerjee A. *Mycobacterium abscessus*: insights from a bioinformatic perspective. Crit Rev Microbiol 2023 Aug;49(4):499-514. (PMID: 35696783)

6. Soverina S, Gilliland HN, Olive AJ. Pathogenicity and virulence of *Mycobacterium abscessus*. Virulence. 2025 Dec;16(1):25088 13. (PMID: 40415550)

7. Parmar S, Tocheva EI. The cell envelope of *Mycobacterium abscessus* and its role in pathogenesis. PLoS Pathog. 2023 May 18; 19(5):e1011318. (PMID: 37200238)

8. Cocorullo M, Stamilla A, Recchia D, Marturano MC, Maci L, Stelitano G. *Mycobacterium abscessus* Virulence Factors: An Overview of Un-Explored Therapeutic Options. Int J Mol Sci 2025 Mar 31;26(7):3247. (PMID: 40244091)

9. Calderaro A, Chezzi C. MALDI-TOF MS: A Reliable Tool in the Real Life of the Clinical Microbiology Laboratory. Microorganisms 2024 Feb 3;12(2):322. (PMID: 38399726)

10. Santos P, Alho I, Ribeiro E. MALDI-TOF MS Biomarkers for Methicillin-Resistant Staphylococcus aureus Detection: A Systematic Review. Metabolites 2025 Aug 8;15(8):540. (PMID: 40863157)

11. Costa MM, Corbel V, Ben Hamouda R, Almeras L. MALDI-TOF MS Profiling and Its Contribution to Mosquito-Borne Diseases: A Systematic Review. Insects 2024 Aug 29;15(9):651. (PMID: 39336619)

12. Zhu Y, Liu Z, Peng L, et al. Evaluation of nucleotide MALDI-TOF-MS for the identification of Mycobacterium species. Front Cell Infect Microbiol 2024 Feb 6;14:1335104. (PMID: 38379773)

13. Mandlik JS, Patil AS, Singh S. Next-Generation Sequencing (NGS): Platforms and Applications. J Pharm Bioallied Sci 2024 Feb;16(Suppl 1):S41-S45. (PMID: 38595613)

14. Domrazek K, Jurka P. Application of Next-Generation Sequencing (NGS) Techniques for Selected Companion Animals. Animals (Basel) 2024 May 27;14(11):1578. (PMID: 38891625)

15. Ramakrishnan R, Washington A, Suveena S, Rani JR, Oommen OV. From DNA to Big Data: NGS Technologies and Their Applications. Methods Mol Biol 2025;2952:459-82. (PMID: 40553348)